



CLINICAL GUIDELINES PROGRAM

NEW YORK STATE DEPARTMENT OF HEALTH AIDS INSTITUTE | HIV · HCV · SUBSTANCE USE · LGBT HEALTH

Prevention and Treatment of Mpox

Updates, Authorship, and Related Guidelines

Date of current publication	May 6, 2024
Intended users	Primary care providers and other clinicians in New York State who provide ambulatory care to individuals with or at risk of acquiring mpox disease
Lead authors	Jacob R. McLean, DO ; Jason E. Zucker, MD
Writing group	Rona M. Vail, MD, AAHIVS; Sanjiv S. Shah, MD, MPH, AAHIVM, AAHIVS; Steven M. Fine, MD, PhD; Joseph P. McGowan, MD, FACP, FIDSA, AAHIVS; Samuel T. Merrick, MD, FIDSA; Asa E. Radix, MD, MPH, PhD, FACP, AAHIVS; Jessica Rodrigues, MPH, MS; Christopher J. Hoffmann, MD, MPH, MSc, FACP; Brianna L. Norton, DO, MPH; Charles J. Gonzalez, MD
Author and writing group conflict of interest disclosures	There are no author or writing group conflict of interest disclosures
Date of original publication	May 6, 2024
Committee	Medical Care Criteria Committee
Developer and funder	New York State Department of Health AIDS Institute (NYSDOH AI)
Development process	See Supplement: Guideline Development and Recommendation Ratings
Related NYSDOH AI guidelines	<ul style="list-style-type: none">• Guidance: Adopting a Patient-Centered Approach to Sexual Health• GOALS Framework for Sexual History Taking in Primary Care• Immunizations for Adults With HIV

Prevention and Treatment of Mpox

Date of current publication: May 6, 2024

Lead author: [Jacob R. McLean, DO](#); [Jason E. Zucker, MD](#)

Writing group: Rona M. Vail, MD, AAHIVS; Sanjiv S. Shah, MD, MPH, AAHIVM, AAHIVS; Steven M. Fine, MD, PhD; Joseph P. McGowan, MD, FACP, FIDSA, AAHIVS; Samuel T. Merrick, MD, FIDSA; Asa E. Radix, MD, MPH, PhD, FACP, AAHIVS; Jessica Rodrigues, MPH, MS; Christopher J. Hoffmann, MD, MPH, MSc, FACP; Brianna L. Norton, DO, MPH; Charles J. Gonzalez, MD

Committee: [Medical Care Criteria Committee](#)

Date of original publication: May 6, 2024

Contents

Purpose of This Guideline	2
Epidemiology	3
Transmission	3
Mpox Prevention.....	4
Immunization.....	5
Post-Exposure Prophylaxis.....	6
Mpox Presentation and Diagnosis	6
Symptoms	7
STI Coinfection and Mpox Differential Diagnoses	8
Mpox Diagnostic Testing.....	8
Transmission Prevention and Infection Control	9
Mpox Treatment	9
Supportive Care	10
Medical Countermeasures.....	10
All Recommendations	12
References	12
Supplement: Guideline Development and Recommendation Ratings	17

Purpose of This Guideline

This guideline was developed by the New York State Department of Health AIDS Institute (NYSDOH AI) to inform primary care providers and other clinicians in New York State about mpox prevention, presentation, diagnosis, and treatment in adults with and without HIV. The goals of this guideline include:

- Increase clinicians' awareness of and ability to recognize the common clinical manifestations of mpox and diagnose the disease in their patients.
- Provide clinicians with evidence-based recommendations on primary prevention, diagnostic testing, and supportive care and treatment of mpox.
- Increase clinicians' awareness of recommended precautions to reduce occupational exposure to and community transmission of mpox.

Terminology: In November 2022, the [Centers for Disease Control and Prevention \(CDC\) aligned its terminology with that of the World Health Organization](#) and adopted the term mpox to refer to monkeypox, to reduce negative effects, including stigma, associated with the use of the term monkeypox. Mpox refers to the disease caused by infection with the human monkeypox virus (MPXV), a member of the *Orthopoxvirus* genus related to the smallpox virus, but the use of the 2 terms and associated abbreviations is not standardized. In this document, the term mpox is used to refer to the virus and the associated disease.

Epidemiology

Mpox was first described in 1970 in the Democratic Republic of Congo and subsequently caused sporadic outbreaks primarily in endemic areas of Central and West Africa. Beginning in May 2022, an outbreak of mpox initially identified in the United Kingdom spread globally, becoming the largest outbreak of this disease to date [Laurenson-Schafer, et al. 2023].

The mpox virus species is subdivided into clades I and II, with clade II further subdivided into IIa and IIb. Clade IIb has driven the most recent mpox outbreak [CDC(a) 2024] and appears to cause less severe symptoms than clade I in animal models [Americo, et al. 2023].

Globally and in the United States, the recent mpox outbreak has affected primarily men who have sex with men (MSM) [McQuiston, et al. 2023], although infections have occurred in people of all sexual orientations, genders, and ages. People with HIV have been disproportionately affected, comprising approximately 38% of U.S. mpox cases [Curran, et al. 2022].

On August 4, 2022, the U.S. Department of Health and Human Services declared the mpox outbreak a [public health emergency](#) but allowed the declaration to expire in January 2023 when cases declined [DHHS 2022]. Available evidence suggests that the decline in cases was driven by the combined effect of behavior modification and vaccine uptake among people vulnerable to mpox [Clay, et al. 2024; Moschese, et al. 2024; Paredes, et al. 2024; Zhang, et al. 2024]. At the time of this publication, mpox incidence has remained low, but cases continue to be reported daily, suggesting endemicity. The CDC has warned about the potential for recurrent mpox outbreaks, especially among MSM in areas or networks with a low prevalence of immunity from prior infection or vaccination [Pollock, et al. 2023]. The CDC also has advised of a significant uptick in clade I mpox in the Democratic Republic of Congo from 2023 to 2024, including in sexual networks. Surveillance for clade I mpox virus is ongoing in the United States, and instructions about how to report possible clade I mpox are noted below [CDC(a) 2023].

→ KEY POINTS

- This guideline is intended to provide guidance for mpox prevention and treatment in general; however, because clade IIb dominated the 2022 worldwide outbreak, the majority of evidence supporting the clinical descriptions and recommendations pertain to clade II mpox.
- For recommendations on testing if clade I mpox is suspected, such as in a patient who traveled to the Democratic Republic of Congo within 21 days [CDC(a) 2023], care providers in New York City can call the Provider Access Line at 1-866-692-3641; care providers in other counties in New York State can call the Office of Sexual Health and Epidemiology at 1-518-474-3598 during business hours or 1-866-881-2809 during evenings, weekends, and holidays. See the [NYSDOH December 12, 2023 Dear Colleague Letter](#) for additional information.

Transmission

Human-to-human transmission of mpox clade IIb occurs primarily via physical contact with an infected individual's skin, saliva, or mucous membranes. In the 2022 mpox outbreak, sexual and other intimate contact is thought to have been the primary, although not exclusive, driver of viral spread [McQuiston, et al. 2023; Tarin-Vicente, et al. 2022; Vaughan, et al. 2022]. Transmission via fomites, usually soft, porous items such as linens, is less common, and respiratory transmission is theoretically possible but has not been formally reported [CDC(e) 2024; Beeson, et al. 2023].

The incubation period for mpox ranges from 3 to 17 days, with a mean of approximately 6 days [Madewell, et al. 2023], and illness may last from 2 to 4 weeks [CDC(b) 2023; Madewell, et al. 2023]. Fortunately, mortality from mpox is low, with only 56 deaths noted among the 31,689 mpox cases reported to the CDC as of January 10, 2024 [CDC(f) 2024]. Notably, of those who died for whom additional case data were available, 94% were immunocompromised due to advanced HIV [Riser, et al. 2023].

Replication-competent virus has been detected for up to 3 weeks from symptom onset in immunocompetent individuals, with the highest burden and longest persistence of replication-competent virus found in skin lesions [Palich, et al. 2023; Suner, et al. 2023]. No cases of mpox transmission have occurred after skin lesions healed. Although there have been cases of *presymptomatic* transmission [CDC(c) 2023; Miura, et al. 2023], the role of transmission in asymptomatic individuals remains unclear [Mizushima, et al. 2023]. The risk of transmission of mpox to healthcare professionals appears low, with the majority of events related to needlestick injuries sustained during attempts to unroof vesicles or lesions [Choi, et al. 2023; Caldas, et al. 2022; Carvalho, et al. 2022; Mendoza, et al. 2022; Zachary and Shenoy 2022].

See Box 1, below, for an overview of the clinical presentation of mpox and strategies for preventing transmission and controlling infection, and see the guideline section [Mpox Presentation and Diagnosis](#) for an in-depth discussion of these topics.

Box 1: Overview of Mpox Clinical Presentation, Transmission Prevention, and Infection Control	
Mpox Clinical Presentation	Transmission Prevention and Infection Control
<ul style="list-style-type: none"> • Mpox is characterized by a skin rash that can be macular, papular, vesicular, or pustular. Lesions in different stages may be present simultaneously. • Skin rash may or may not be accompanied by a systemic prodrome of fever, malaise, headache, myalgias, and lymphadenopathy. • Mucosal involvement, especially proctitis or pharyngitis, is common. • Coinfection with sexually transmitted infections is common. • Immunocompromised individuals, including those with advanced HIV, are more likely to develop severe manifestations. 	<p>Healthcare providers: Use of personal protective equipment, including a gown, gloves, eyewear, and an N-95 or comparable respirator mask, will help prevent occupational exposure in healthcare providers who are evaluating or collecting a specimen from a patient with suspected mpox. There is no need to unroof lesions before swabbing, and this practice may increase the risk of needlestick injury and occupational infection [CDC(c) 2024].</p> <p>Patients: Although, ideally, patients with mpox will isolate at home and remain separate from other people, this may not always be feasible. To reduce the risk of community transmission, advise patients with confirmed or suspected mpox to do the following until all lesions have healed and other symptoms have resolved:</p> <ul style="list-style-type: none"> • Avoid skin-to-skin and sexual contact • Avoid sharing clothing, bed linens, and other soft, porous materials that may have come into contact with a lesion • Avoid sharing eating or personal hygiene utensils, such as razors; if items must be shared, wash and disinfect after each use • Avoid exposing other people to lesions; if an individual with mpox lesions must be in shared or public spaces, covering all lesions with clothing, bandages, or gloves can prevent transmission • Wear a medical mask if in close proximity with other people for more than a brief encounter (per CDC) <p>See CDC Mpox > Isolation and Infection Control at Home for more information, including disinfection strategies.</p>
<p>Abbreviation: CDC, Centers for Disease Control and Prevention.</p>	

Mpox Prevention

RECOMMENDATIONS

Mpox Prevention

- Clinicians should recommend the MVA 2-dose vaccine series to individuals ≥ 18 years old who are at risk of acquiring mpox. (A2)
- Clinicians should recommend the MVA 2-dose vaccine series to individuals between 6 months and 18 years old who are at risk of acquiring mpox [a]. (A3)
- Clinicians should encourage individuals being vaccinated with MVA to receive *both* doses in the series for optimal protection. (A2)
- Clinicians should not offer vaccination to individuals with prior laboratory-confirmed mpox. (A3)
- Clinicians should recommend the MVA vaccine as PEP to individuals who have been exposed to mpox within the past 14 days and for whom vaccination may reduce the risk of infection or decrease symptoms if infection has occurred. (A2)
- Clinicians should vaccinate individuals with HIV who are at risk of acquiring mpox regardless of CD4 count or viral load. (A2)

Abbreviations: EUA, emergency use authorization; FDA, U.S. Food and Drug Administration; MVA, modified vaccinia Ankara (brand name JYNNEOS); PEP, post-exposure prophylaxis.

Note:

- a. In August 2022, the FDA issued an [EUA for emergency use of the JYNNEOS vaccine in individuals <18 years old](#).

As noted above, behavior changes and vaccine uptake are thought to have driven the rapid decline in mpox cases that occurred in the summer of 2022, underscoring the importance of patient education to promote prevention among those vulnerable to mpox. The sections below contain information related to mpox risk and MVA vaccine efficacy, safety, and use as PEP, all of which can help healthcare providers counsel their patients about mpox prevention.

Immunization

Primary prevention through immunization is a cornerstone of mpox epidemic control. The currently recommended mpox vaccine, brand name JYNNEOS, is based on MVA, a nonreplicating live virus vaccine originally developed as part of the global smallpox eradication effort. MVA is incapable of replication within human hosts, and because it is nonreplicating, exposure to MVA *cannot* result in infection, unlike prior versions of the smallpox vaccine.

The MVA vaccine is approved by the FDA for use in people ≥ 18 years old. In August 2022, the FDA issued an [EUA for emergency use of the JYNNEOS vaccine in individuals <18 years old](#). Although clinical efficacy data in this population are not yet available, the vaccine has been shown to be safe and immunogenic [Ladhani, et al. 2023]. When considering vaccination of infants younger than 6 months old, clinicians should contact their jurisdictional health department.

Mpx immunization for primary prevention is recommended for individuals at elevated risk of infection, including but not limited to those in the groups listed in Box 2, below. Following the commercialization of the MVA vaccine, all individuals requesting vaccination or who believe they may be vulnerable to mpox can be considered for vaccination. Estimates of vaccine efficacy range from 36% to 86% for 1 dose and increase to 66% to 89% two weeks after administration of the second dose or completion of the 2-dose series [Bertran, et al. 2023; Dalton, et al. 2023; Deputy(a), et al. 2023; Deputy(b), et al. 2023; Rosenberg, et al. 2023; Wolff Sagy, et al. 2023]. Reports of breakthrough mpox in fully vaccinated individuals suggest that symptoms may be milder than in those with no preexisting immunity [Hazra, et al. 2024; Farrar, et al. 2022]. Infection with the human mpox virus generates a robust immune response [Agrati, et al. 2023]. At the time of publication, mpox immunization is not advised for individuals who have had prior laboratory-confirmed mpox. People reporting a history of symptoms consistent with mpox but without confirmatory testing should still be offered vaccination if otherwise indicated.

Administration: MVA is licensed for subcutaneous administration in a 2-dose series, with injections spaced 28 days apart. If the second dose is not given at 28 days, it should be administered as soon as possible thereafter. If the second dose is given less than 4 days early, the vaccine series does not need to be repeated [CDC(d) 2024]. Intradermal vaccination was used in the context of product shortages during the 2022 epidemic and appeared to generate antibody responses comparable to subcutaneous injection [Brooks, et al. 2022] but was also associated with a higher risk of local cutaneous adverse reactions and potentially lasting hyperpigmentation [Frey, et al. 2023; Frey, et al. 2015]. For this reason, subcutaneous administration is the preferred route when supplies allow. Intradermal administration is not approved under the EUA for individuals younger than 18 years old.

Individuals with HIV: Given the disproportionate burden of mpox among people with HIV [Curran, et al. 2022], vaccination of those at risk is a priority. Of note, although other smallpox vaccine products may confer some protection against mpox, MVA is the only vaccine that is safe for use in people with HIV [CDC(b) 2024] and appears to have reliable immunogenicity in individuals without advanced immunocompromise [Overton, et al. 2020; Greenberg, et al. 2013]. Although MVA is technically a live vaccine, the virus does not replicate in human hosts and is not contraindicated in individuals with advanced HIV. Little is known about the immunogenicity of the MVA vaccine in people with HIV and advanced immunosuppression, but mpox vaccination should be offered regardless of immune status.

Individuals who are pregnant or breastfeeding: Limited data are available regarding the safety or associated risks of the MVA vaccine for individuals who are pregnant or breastfeeding. However, animal studies have found no risk to a developing fetus, and the replication-deficient nature of the MVA virus means there should be no risk of infection in breastfed infants [Rao, et al. 2022]. Healthcare providers may offer mpox vaccination as primary prophylaxis or PEP after engaging pregnant or breastfeeding individuals in shared decision-making that includes evaluation of known risks versus benefits.

Box 2: [Centers for Disease Control and Prevention Recommendations for Mpox Vaccination](#)

Mpox vaccination should be offered to:

- People who had known or suspected exposure to someone with mpox
- People who had a sex partner in the past 2 weeks who was diagnosed with mpox
- Gay, bisexual, and other men who have sex with men, and transgender or nonbinary people (including adolescents who fall into any of these categories) who, in the past 6 months, have had:
 - A new diagnosis of 1 or more sexually transmitted infections (e.g., chlamydia, gonorrhea, syphilis)
 - More than 1 sex partner
- People who have had any of the following in the past 6 months:
 - Sex at a commercial sex venue
 - Sex in association with a large public event in a geographic area where mpox transmission is occurring
 - Sex in exchange for money or other items
- People who are sex partners of people with the above risks
- People who anticipate experiencing any of the above scenarios
- People with HIV or other causes of immunosuppression who have had recent or anticipate potential mpox exposure
- People who work with orthopoxviruses in a laboratory

Post-Exposure Prophylaxis

When administered as PEP within 14 days of mpox exposure, the MVA vaccine reduced the chance of symptomatic infection and symptom severity [Montero Morales, et al. 2023]. Precise estimates of the efficacy of this strategy are lacking, given the bias inherent in retrospective analysis [Rosen, et al. 2024; Deputy(b), et al. 2023]. Future research may answer this question [Luong Nguyen, et al. 2022]. Despite these limitations, asymptomatic individuals without prior immunity who have been exposed to mpox in the last 14 days should be offered vaccination as PEP, ideally within 4 days after exposure, to reduce the risk of infection or decrease symptoms. Individuals receiving vaccine PEP should be encouraged to complete the full vaccine series even in the absence of symptoms.

Mpox Presentation and Diagnosis

RECOMMENDATIONS

Mpox Presentation and Diagnosis

- Before evaluating people with suspected mpox, clinicians should don personal protective equipment, including a gown, an N95 respirator or comparable mask, eye protection, and gloves. (A3)
- To diagnose mpox, clinicians should obtain 4 swabs for PCR testing: 2 specimens each taken from swabs of 2 skin lesions, whenever possible, preferably in different stages and at different body sites, without unroofing lesions. (A3)
- Clinicians should recommend HIV antibody/antigen testing and STI testing (e.g., syphilis serologies and exposure-site gonorrhea and chlamydia NAAT) for any patient with suspected or confirmed sexually acquired mpox. (A3)
 - See the NYSDOH AI guideline [HIV Testing](#).
- Clinicians should recommend that patients with suspected or confirmed mpox avoid exposing others to lesions [a] to reduce mpox transmission. (A*)

Abbreviations: NAAT, nucleic acid amplification testing; PCR, polymerase chain reaction; STI, sexually transmitted infection.

Note:

- Transmission prevention recommendations:** Isolate in the home if feasible; avoid skin-to-skin and sexual contact; avoid sharing clothing, bed linens, and other soft, porous materials that may have come into contact with a lesion; avoid sharing eating or personal hygiene utensils, such as razors; if items must be shared, wash and disinfect after each use; avoid exposing other people to lesions; when in public or shared spaces, cover all lesions with clothing, bandages, or gloves; wear a medical mask if in close proximity with other people for more than a brief encounter (per the Centers for Disease Control and Prevention). Continue these precautions until all mpox lesions have crusted, those crusts have separated, and a new layer of skin has formed underneath.

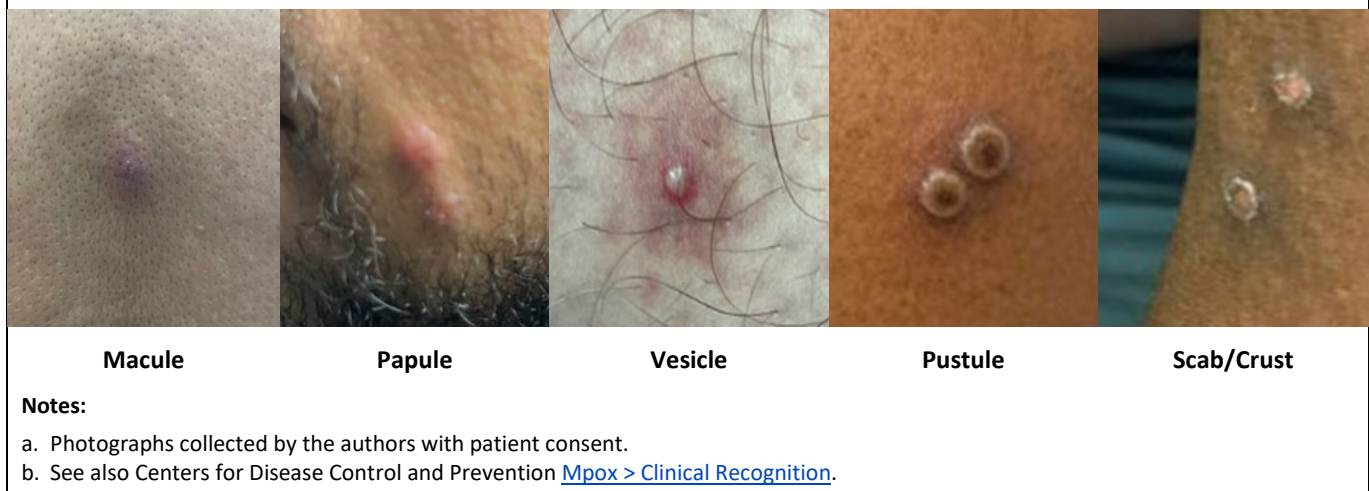
Symptoms

Systemic symptoms including fever, headache, myalgias, lymphadenopathy, and malaise were commonly described as the presenting symptoms in mpox cases before the 2022 outbreak [Titanji, et al. 2022; Ogoina, et al. 2020]. Although most people with mpox will experience systemic symptoms at some point in the course of their infection, rash has been the initial manifestation in approximately 50% of recent cases [Mailhe, et al. 2023; Philpott, et al. 2022]. Lymphadenopathy localized around sites of mucosal involvement is more common than generalized lymphadenopathy.

Rash: Mpox is characterized by lesions on the skin and mucous membranes. During the 2022 mpox outbreak, rash was observed most often in the anogenital area but was also found on the mouth, hands, face, feet, or chest [Philpott, et al. 2022; Thornhill, et al. 2022]. Lesions classically progress from macule to papule to pustule or vesicle before crusting and, ultimately, healing with new skin formation in 2 to 4 weeks. During the 2022 mpox outbreak, it was common for patients to have lesions in multiple stages on the same body part at the same time [CDC(b) 2023].

The most typical lesions are pustules or vesicles that are often umbilicated, deep-seated, and painful. Rash extent varies considerably, ranging from a single lesion to disseminated disease. Open lesions can develop bacterial superinfection, resulting in cellulitis or abscess in the surrounding skin. Figure 1, below, shows examples of characteristic lesions.

Figure 1: Stages of Mpox Lesions



Mucosal involvement: Mucosal involvement may occur at the site of exposure and is responsible for much of the morbidity of mpox [Tarin-Vicente, et al. 2022]. Proctitis was noted in 20% to 30% of cases in the 2022 mpox outbreak [Cassir, et al. 2022; Català, et al. 2022; Tarin-Vicente, et al. 2022] and may be present without visible perianal lesions. Typical symptoms of pain, tenesmus, and discharge may be accompanied by diarrhea or constipation. Oropharyngeal involvement, which has been noted in 22% of cases, is also common and may lead to odynophagia that interferes with eating or drinking [Gandhi, et al. 2023; Shah, et al. 2023].

Ocular disease: Ophthalmologic manifestations, including keratitis, conjunctivitis, or blepharitis, may occur through autoinoculation and can cause lasting vision impairment [Abdelaal, et al. 2023; Cash-Goldwasser, et al. 2022].

Severe disease: Severe necrotizing mpox is more common in immunocompromised individuals, including those with advanced HIV. Severe disease may include a higher lesion burden and other organ involvement, such as pneumonitis or encephalitis. Of note, individuals with well-controlled HIV present with symptoms similar to those in individuals without HIV [McLean, et al. 2023].

→ KEY POINT

- Test for mpox in patients who present with a rash that is potentially consistent with mpox, especially if epidemiologic criteria are present or a known exposure has occurred, regardless of vaccination status or prior infection.

STI Coinfection and Mpox Differential Diagnoses

Many patients presenting with mpox symptoms will have other STIs that may have overlapping symptoms. Herpes simplex virus lesions can be particularly difficult to distinguish from mpox lesions. Obtaining a [detailed sexual history](#), considering additional or alternative processes, and offering STI screening when indicated are critical when evaluating a patient with suspected mpox.

Table 1, below, outlines common differential diagnoses based on clinical syndrome and features that may distinguish mpox from other infections. The *British Medical Journal* (BMJ) also provides a comprehensive list of infectious and noninfectious differentials: [BMJ Best Practice > Mpox Diagnosis > Differentials](#).

Table 1: Common Differential Diagnoses for Clinical Syndromes Caused by Mpox	
Clinical Syndrome	Common Differential Diagnoses and Distinguishing Features
Rash, localized or general	<ul style="list-style-type: none"> • Herpes simplex virus: History of prior outbreaks is common; generalized rash is less common; systemic symptoms are uncommon with localized rash • Varicella zoster virus: Dermatomal distribution (shingles); isolated anogenital involvement is less common • Molluscum contagiosum: Lesions are typically painless; systemic symptoms, mucosal involvement, and lesions on palms or soles are less common • Secondary syphilis: Rash typically presents without vesicles or umbilication, though can be ulcerated or pustular • Acute HIV: Umbilication of skin lesions and anogenital involvement are uncommon
Genital ulcer	<ul style="list-style-type: none"> • Herpes simplex virus: History of prior outbreaks is common; systemic symptoms are rare • Primary syphilis: Typically painless • Lymphogranuloma venereum: Ulcer is typically painless and often resolved at the time of presentation • Chancroid: Currently rare in the United States
Proctitis	<ul style="list-style-type: none"> • Gonorrhea: No papular or vesicular lesions; no systemic symptoms • Chlamydia (serovars D-K): No papular or vesicular lesions; no systemic symptoms • Lymphogranuloma venereum: Genital ulcer is typically not concurrent with proctitis • Secondary syphilis: Can present with a rectal mass, but genital ulcers are generally not concurrent • Herpes simplex virus: History of prior outbreaks is common • Enteric bacteria: No ulcers; no skin or mucosal lesions

Mpox Diagnostic Testing

Mpox is diagnosed via PCR analysis of skin lesion specimens. Whenever possible, to maximize sensitivity, 2 specimens should be collected from each of 2 separate lesions, preferably in different stages and at different body sites (4 swabs in total). When feasible, sanitize the patient’s skin with an alcohol wipe and allow the skin to air dry. Rub swabs vigorously on the base of the lesion to ensure adequate transfer of cells onto the swab surface. Lesions should not be unroofed before swabbing because this practice may increase the risk of needlestick injury and occupational infection [CDC(c) 2024].

If a patient has no skin lesions, mpox virus may be detected in other compartments such as the throat or rectum, although testing at these sites is not approved by the U.S. Food and Drug Administration. In patients with skin lesions, testing additional sites does not increase the chance of diagnosis because skin lesions have the highest viral loads and longest clearing time [Palich, et al. 2023; Suner, et al. 2023].

Synthetic swabs (not cotton) can be submitted dry or in viral or universal transport media. Bacterial transport media should be avoided because this can interfere with PCR assays. Depending on the laboratory facility used, crusts taken from lesions may also be acceptable specimens. Confirm requirements with the laboratory facility processing the specimen. Many commercial laboratories offer mpox testing, as do the [NYSDOH Wadsworth Center](#) and [New York City Public Health Laboratory](#).

Anyone with suspected or diagnosed mpox potentially contracted via sexual contact should receive HIV antibody/antigen testing, syphilis serologies, and gonorrhea and chlamydia NAAT of the urine, cervix, rectum, or pharynx depending on site(s) of exposure. See the NYSDOH AI guideline [HIV Testing](#).

In response to an ongoing outbreak of clade I mpox virus in the Democratic Republic of Congo (DRC), the Centers for Disease Control and Prevention (CDC) recommend that individuals with suspected mpox who have traveled to the DRC within the previous 21 days undergo clade-specific testing [CDC(a) 2023]. For consultation about testing and treatment of such individuals, care providers in New York City can call the Provider Access Line at 1-866-692-3641; care providers in other counties in New York State can call the Office of Sexual Health and Epidemiology at 1-518-474-3598 during business hours or 1-866-881-2809 during evenings, weekends, and holidays. See the [NYSDOH December 12, 2023 Dear Colleague Letter](#) for additional information.

See NYSDOH [Guidance on Testing at Commercial and Public Health Laboratories](#) and CDC [Guidelines for Collecting and Handling Specimens for Mpox Testing](#) for additional guidance on best practices for mpox specimen collection.

☆ NEW YORK STATE LAW

Per [New York State Public Health Law](#), all positive mpox test results must be reported to the local health department. See the following for more information:

- [Mpox for Healthcare Providers > Case Reporting](#)
- [Health Advisory: Mpox Cases Associated With Person-to-Person Transmission](#)

Transmission Prevention and Infection Control

Preventing occupational mpox exposure: Healthcare providers should practice effective hand hygiene and don personal protective equipment (gown, gloves, eyewear, and an N-95 or comparable respirator mask) before evaluating or collecting a specimen from a patient with suspected mpox. See the guideline section [Purpose of This Guideline > Transmission](#) for discussion of routes of potential mpox exposure.

Preventing community mpox transmission: Healthcare providers should recommend that patients with mpox take the following precautions to protect others from exposure and prevent transmission:

- Isolate in the home if feasible
- Avoid skin-to-skin and sexual contact
- Avoid sharing clothing, bed linens, and other soft, porous materials that may have come into contact with a lesion
- Avoid sharing eating or personal hygiene utensils, such as razors; if items must be shared, wash and disinfect after each use
- Avoid exposing other people to lesions when in public or shared spaces; cover all lesions with clothing, bandages, or gloves
- Wear a medical mask if in close proximity with other people for more than a brief encounter ([per the CDC](#))

In individuals with suspected mpox, the above precautions should be continued until mpox has been ruled out. For those with confirmed mpox, precautions should be continued until all lesions have crusted, crusts have separated, and a new layer of skin has formed underneath.

See CDC [Mpox > Isolation and Infection Control at Home](#) for more information, including disinfection strategies.

Mpox Treatment

Fortunately, the prognosis of mpox in the context of the 2022 clade IIb mpox outbreak is excellent, and the majority of affected individuals recover fully whether they receive medical attention or not [CDC(f) 2024]. Supportive measures for pain and other symptom control as well as treatment of complications, such as bacterial superinfection, are the mainstays of therapy. Although there is no U.S. Food and Drug Administration (FDA)-approved therapy specifically for mpox, several antiviral medications developed for the treatment of infection with other pathogens have been repurposed as mpox medical countermeasures.

Supportive Care

Many patients with mpox will experience significant pain from skin lesions or mucosal involvement, including proctitis or pharyngitis. Although there is limited empirical evidence, the Centers for Disease Control and Prevention (CDC) has provided [clinical considerations for supportive care and pain management of mpox](#) based on the clinical experience of healthcare providers. Pain can often be controlled with over-the-counter analgesics such as acetaminophen or nonsteroidal anti-inflammatory medications. Some individuals may require treatment with gabapentin or opioid medications for severe pain. For patients with opioid use disorder on medication-assisted treatment, consider recommendations available in the U.S. Department of Veteran’s Affairs [Evidence Brief: Managing Acute Pain in Patients with Opioid Use Disorder on Medication-assisted Treatment](#).

Topical therapies such as sitz baths for proctitis and saltwater or viscous lidocaine gargles for pharyngitis can also be used. Stool softeners can offer relief for painful defecation with proctitis and can also be considered for patients treated with opioids. When bacterial superinfection of mpox skin lesions is suspected, the recommended treatment is topical or systemic antibiotics as per usual for skin and soft tissue infections. Table 2, below, outlines supportive care measures for complications associated with mpox.

Table 2: Supportive Care Measures for Mpox Complications		
Proctitis	Pharyngitis	Genital lesions
<ul style="list-style-type: none"> • Stool softeners • Sitz baths • Lidocaine gel • Nonsteroidal anti-inflammatory medications • Gabapentin • Opioids (if indicated, see guidance referenced above) 	<ul style="list-style-type: none"> • Saltwater gargles • Viscous lidocaine • Magic mouthwash • Oral antiseptics • Nonsteroidal anti-inflammatory medications • Opioids (if indicated) 	<ul style="list-style-type: none"> • Frequent bathing • Keep lesions clean and dry • If infected: Wet-to-dry dressings, systemic antibiotics

Medical Countermeasures

Tecovirimat: Tecovirimat has been the preferred antiviral agent during the 2022 mpox outbreak. It was originally developed for the treatment of smallpox (caused by variola, another orthopoxvirus) and approved by the FDA in 2018 through the animal rule based on animal efficacy studies. This medication acts by targeting the p37 protein, a component of the viral envelope in the mpox virus and related orthopoxviruses [DeLaurentis, et al. 2022]. Tecovirimat was made available through an expanded access investigational new drug (EA-IND) protocol and has been provided to more than 6,800 people during the 2022 mpox outbreak. To date, only mild adverse effects have been reported in safety data [O’Laughlin, et al. 2022], with mixed results on efficacy in observational data [Akiyama, et al. 2024; Karmarkar, et al. 2024; Mazzotta, et al. 2023]. Surveillance data demonstrated the development of resistance in immunocompromised individuals requiring extended courses of tecovirimat, and presumed transmitted resistance has been identified in individuals not exposed to tecovirimat [Garrigues(a), et al. 2023; Garrigues(b), et al. 2023].

Clinicians are encouraged to inform all individuals with presumed or confirmed mpox about the [NIH STOMP study](#), which is the primary means of access to tecovirimat. This study, underway since September 2022, is a placebo-controlled double-blind clinical trial with a 2:1 randomization scheme designed to measure the effect of tecovirimat on time to mpox resolution. Individuals who have or are at risk of developing severe mpox, children, and individuals who are pregnant or breastfeeding are allocated to an open-label study arm and will receive tecovirimat. Remote enrollment is available for those not near a study site. The call center listed at the link above can direct healthcare providers to nearby study sites or options for remote enrollment.

Patients who do not wish to or are unable to participate in the [NIH STOMP study](#) and patients who require intravenous tecovirimat may be eligible to receive the medication through the [CDC EA-IND protocol](#). This is available only to individuals who have or are at risk of developing severe disease. Care providers should work in concert with their county health department to request a supply of tecovirimat by calling the CDC Emergency Operations Center at 770-488-7100 or emailing poxxvirus@cdc.gov.

Cidofovir and brincidofovir: Cidofovir and its derivative, brincidofovir, are antiviral drugs that block DNA polymerase, thus stopping further DNA synthesis and leading to nonproductive infection. Cidofovir is approved by the FDA for intravenous treatment of cytomegalovirus retinitis. Animal studies suggest cidofovir might be effective against orthopoxviruses, but there are no human data yet to confirm its effectiveness in treating mpox. Because of the risk of cidofovir-associated kidney damage, its intravenous form is typically reserved for severe cases of mpox [Rao, et al. 2023], especially in patients with significant immunosuppression. Topical cidofovir has been used as a cream or injected directly into lesions, and case reports have noted improvements when cidofovir was used in this way [Buechler, et al. 2023]. Brincidofovir is thought to be less harmful to the kidneys but may lead to adverse effects such as diarrhea and liver damage. Animal studies suggest a synergistic effect between brincidofovir and tecovirimat [Quenelle, et al. 2007]. Brincidofovir is also approved via the animal rule and [is available as an EA-IND](#) for mpox treatment.

Vaccinia immune globulin intravenous (VIGIV): VIGIV treatment involves the administration of antibodies targeting the vaccinia virus and is thought to offer some protection against mpox [Rao, et al. 2023]. This therapy can be particularly advantageous for individuals with compromised immune systems, such as those with advanced HIV, who may be unable to produce an adequate antibody response to infection [Thet, et al. 2023].

Use of cidofovir, brincidofovir, and vaccine immunoglobulins has been limited to patients with severe disease and should occur only in consultation with an experienced specialist or the CDC Clinical Consultation Team, available by email at poxvirus@CDC.gov.

Information on how to access all the medical countermeasures discussed above can be found at CDC [Treatment Information for Healthcare Professionals](#).

Trifluridine: The topical antiviral agent trifluridine has in vitro activity against orthopoxviruses and is approved by the FDA for treatment of eye infections caused by herpes simplex virus [Cinatl, et al. 2024; Pepose, et al. 2003; Hyndiuk, et al. 1976]. Although efficacy for ocular mpox has not been established, trifluridine was used in the 2022 outbreak with anecdotal success [Perzia, et al. 2023]. Trifluridine can be offered to patients with mpox ocular disease, preferably in consultation with an ophthalmologist.

All Recommendations

☑ ALL RECOMMENDATIONS: PREVENTION AND TREATMENT OF MPOX

Mpox Prevention

- Clinicians should recommend the MVA 2-dose vaccine series to individuals ≥ 18 years old who are at risk of acquiring mpox. (A2)
- Clinicians should recommend the MVA 2-dose vaccine series to individuals between 6 months and 18 years old who are at risk of acquiring mpox [a]. (A3)
- Clinicians should encourage individuals being vaccinated with MVA to receive *both* doses in the series for optimal protection. (A2)
- Clinicians should not offer vaccination to individuals with prior laboratory-confirmed mpox. (A3)
- Clinicians should recommend the MVA vaccine as PEP to individuals who have been exposed to mpox within the past 14 days and for whom vaccination may reduce the risk of infection or decrease symptoms if infection has occurred. (A2)
- Clinicians should vaccinate individuals with HIV who are at risk of acquiring mpox regardless of CD4 count or viral load. (A2)

Mpox Presentation and Diagnosis

- Before evaluating people with suspected mpox, clinicians should don personal protective equipment, including a gown, an N95 respirator or comparable mask, eye protection, and gloves. (A3)
- To diagnose mpox, clinicians should obtain 4 swabs for PCR testing: 2 specimens each taken from swabs of 2 skin lesions, whenever possible, preferably in different stages and at different body sites, without unroofing lesions. (A3)
- Clinicians should recommend HIV antibody/antigen testing and STI testing (e.g., syphilis serologies and exposure-site gonorrhea and chlamydia NAAT) for any patient with suspected or confirmed sexually acquired mpox. (A3)
 - See the NYSDOH AI guideline [HIV Testing](#).
- Clinicians should recommend that patients with suspected or confirmed mpox avoid exposing others to lesions [b] to reduce mpox transmission. (A*)

Abbreviations: EUA, emergency use authorization; FDA, U.S. Food and Drug Administration; MVA, modified vaccinia Ankara (brand name JYNNEOS); NAAT, nucleic acid amplification testing; PEP, post-exposure prophylaxis; PCR, polymerase chain reaction; STI, sexually transmitted infection.

Notes:

- In August 2022, the FDA issued an [EUA for emergency use of the JYNNEOS vaccine in individuals <18 years old](#).
- Transmission prevention recommendations:** Isolate in the home if feasible; avoid skin-to-skin and sexual contact; avoid sharing clothing, bed linens, and other soft, porous materials that may have come into contact with a lesion; avoid sharing eating or personal hygiene utensils, such as razors; if items must be shared, wash and disinfect after each use; avoid exposing other people to lesions; when in public or shared spaces, cover all lesions with clothing, bandages, or gloves; wear a medical mask if in close proximity with other people for more than a brief encounter (per the Centers for Disease Control and Prevention). Continue these precautions until all mpox lesions have crusted, those crusts have separated, and a new layer of skin has formed underneath.

References

- Abdelaal A, Serhan HA, Mahmoud MA, et al. Ophthalmic manifestations of monkeypox virus. *Eye (Lond)* 2023;37(3):383-85. [PMID: 35896700] <https://pubmed.ncbi.nlm.nih.gov/35896700>
- Agrati C, Cossarizza A, Mazzotta V, et al. Immunological signature in human cases of monkeypox infection in 2022 outbreak: an observational study. *Lancet Infect Dis* 2023;23(3):320-30. [PMID: 36356606] <https://pubmed.ncbi.nlm.nih.gov/36356606>
- Akiyama Y, Morioka S, Tsuzuki S, et al. Efficacy and viral dynamics of tecovirimat in patients with MPOX: a multicenter open-label, double-arm trial in Japan. *J Infect Chemother* 2024;30(6):488-93. [PMID: 38042298] <https://pubmed.ncbi.nlm.nih.gov/38042298>
- Americo JL, Earl PL, Moss B. Virulence differences of mpox (monkeypox) virus clades I, IIa, and IIb.1 in a small animal model. *Proc Natl Acad Sci U S A* 2023;120(8):e2220415120. [PMID: 36787354] <https://pubmed.ncbi.nlm.nih.gov/36787354>

- Beeson A, Styczynski A, Hutson CL, et al. Mpox respiratory transmission: the state of the evidence. *Lancet Microbe* 2023;4(4):e277-83. [PMID: 36898398] <https://pubmed.ncbi.nlm.nih.gov/36898398>
- Bertran M, Andrews N, Davison C, et al. Effectiveness of one dose of MVA-BN smallpox vaccine against mpox in England using the case-coverage method: an observational study. *Lancet Infect Dis* 2023;23(7):828-35. [PMID: 36924787] <https://pubmed.ncbi.nlm.nih.gov/36924787>
- Brooks JT, Marks P, Goldstein RH, et al. Intradermal vaccination for monkeypox - benefits for individual and public health. *N Engl J Med* 2022;387(13):1151-53. [PMID: 36044621] <https://pubmed.ncbi.nlm.nih.gov/36044621>
- Buechler CR, Anderson Z, Kullberg SA, et al. Successful treatment of recalcitrant mpox lesions with intralesional cidofovir in a patient with HIV/AIDS. *JAMA Dermatol* 2023;160(2):235-36. [PMID: 38055229] <https://pubmed.ncbi.nlm.nih.gov/38055229>
- Caldas JP, Valdoeiros SR, Rebelo S, et al. Monkeypox after occupational needlestick injury from pustule. *Emerg Infect Dis* 2022;28(12):2516-19. [PMID: 36252152] <https://pubmed.ncbi.nlm.nih.gov/36252152>
- Carvalho LB, Casadio LVB, Polly M, et al. Monkeypox virus transmission to healthcare worker through needlestick injury, Brazil. *Emerg Infect Dis* 2022;28(11):2334-36. [PMID: 36121391] <https://pubmed.ncbi.nlm.nih.gov/36121391>
- Cash-Goldwasser S, Labuda SM, McCormick DW, et al. Ocular monkeypox - United States, July-September 2022. *MMWR Morb Mortal Wkly Rep* 2022;71(42):1343-47. [PMID: 36264836] <https://pubmed.ncbi.nlm.nih.gov/36264836>
- Cassir N, Cardona F, Tissot-Dupont H, et al. Observational cohort study of evolving epidemiologic, clinical, and virologic features of monkeypox in Southern France. *Emerg Infect Dis* 2022;28(12):2409-15. [PMID: 36241422] <https://pubmed.ncbi.nlm.nih.gov/36241422>
- Català A, Clavo-Escribano P, Riera-Monroig J, et al. Monkeypox outbreak in Spain: clinical and epidemiological findings in a prospective cross-sectional study of 185 cases. *Br J Dermatol* 2022;187(5):765-72. [PMID: 35917191] <https://pubmed.ncbi.nlm.nih.gov/35917191>
- CDC(a). Mpox caused by human-to-human transmission of monkeypox virus with geographic spread in the Democratic Republic of the Congo. 2023 Dec 7. <https://emergency.cdc.gov/han/2023/han00501.asp> [accessed 2024 Mar 28]
- CDC(a). About mpox. 2024 Apr 18. <https://www.cdc.gov/poxvirus/mpox/about/index.html> [accessed 2024 Feb 25]
- CDC(b). Mpox: clinical recognition. 2023 Aug 30. <https://www.cdc.gov/poxvirus/mpox/clinicians/clinical-recognition.html> [accessed]
- CDC(b). Clinical considerations for treatment and prophylaxis of mpox infection in people who are immunocompromised. 2024 Apr 15. <https://www.cdc.gov/poxvirus/mpox/clinicians/people-with-HIV.html> [accessed 2024 Feb 15]
- CDC(c). Science brief: detection and transmission of mpox (formerly monkeypox) virus during the 2022 clade IIb outbreak. 2023 Feb 2. <https://stacks.cdc.gov/view/cdc/124367> [accessed 2024 Feb 15]
- CDC(c). Guidelines for collecting and handling specimens for mpox testing. 2024 Apr 29. <https://www.cdc.gov/poxvirus/mpox/clinicians/prep-collection-specimens.html> [accessed 2024 Feb 15]
- CDC(d). Interim clinical considerations for use of JYNNEOS vaccine for mpox prevention in the United States. 2024 Apr 22. <https://www.cdc.gov/poxvirus/mpox/clinicians/vaccines/vaccine-considerations.html> [accessed 2024 Mar 28]
- CDC(e). Mpox: how it spreads. 2024 Mar 1. <https://www.cdc.gov/poxvirus/mpox/if-sick/transmission.html> [accessed 2024 Feb 15]
- CDC(f). Mpox: ongoing 2022 global outbreak cases and data. 2024 Mar 5. <https://www.cdc.gov/poxvirus/mpox/response/2022/index.html> [accessed 2024 Mar 1]
- Choi Y, Jeon EB, Kim T, et al. Case report and literature review of occupational transmission of monkeypox virus to healthcare workers, South Korea. *Emerg Infect Dis* 2023;29(5):997-1001. [PMID: 36856759] <https://pubmed.ncbi.nlm.nih.gov/36856759>
- Cinatil J, Bechtel M, Reus P, et al. Trifluridine for treatment of mpox infection in drug combinations in ophthalmic cell models. *J Med Virol* 2024;96(1):e29354. [PMID: 38180134] <https://pubmed.ncbi.nlm.nih.gov/38180134>
- Clay PA, Asher JM, Carnes N, et al. Modelling the impact of vaccination and sexual behaviour adaptations on mpox cases in the USA during the 2022 outbreak. *Sex Transm Infect* 2024;100(2):70-76. [PMID: 38050171] <https://pubmed.ncbi.nlm.nih.gov/38050171>
- Curran KG, Eberly K, Russell OO, et al. HIV and sexually transmitted infections among persons with monkeypox - eight U.S. jurisdictions, May 17-July 22, 2022. *MMWR Morb Mortal Wkly Rep* 2022;71(36):1141-47. [PMID: 36074735] <https://pubmed.ncbi.nlm.nih.gov/36074735>
- Dalton AF, Diallo AO, Chard AN, et al. Estimated effectiveness of JYNNEOS vaccine in preventing mpox: a multijurisdictional case-control study - United States, August 19, 2022-March 31, 2023. *MMWR Morb Mortal Wkly Rep* 2023;72(20):553-58. [PMID: 37200229] <https://pubmed.ncbi.nlm.nih.gov/37200229>

- DeLaurentis CE, Kiser J, Zucker J. New perspectives on antimicrobial agents: tecovirimat for treatment of human monkeypox virus. *Antimicrob Agents Chemother* 2022;66(12):e0122622. [PMID: 36374026]
<https://pubmed.ncbi.nlm.nih.gov/36374026>
- Deputy(a) NP, Gerhart JL, Feldstein LR. Vaccine effectiveness against mpox in the United States. *N Engl J Med* 2023;389(15):1440-41. [PMID: 37819967] <https://pubmed.ncbi.nlm.nih.gov/37819967>
- Deputy(b) NP, Deckert J, Chard AN, et al. Vaccine effectiveness of JYNNEOS against mpox disease in the United States. *N Engl J Med* 2023;388(26):2434-43. [PMID: 37199451] <https://pubmed.ncbi.nlm.nih.gov/37199451>
- DHHS. Statement from HHS Secretary Becerra on mpox. 2022 Dec 2.
<https://www.hhs.gov/about/news/2022/12/02/statement-from-hhs-secretary-becerra-on-mpox.html> [accessed 2024 Feb 15]
- Farrar JL, Lewis NM, Houck K, et al. Demographic and clinical characteristics of mpox in persons who had previously received 1 dose of JYNNEOS vaccine and in unvaccinated persons - 29 U.S. jurisdictions, May 22-September 3, 2022. *MMWR Morb Mortal Wkly Rep* 2022;71(5152):1610-15. [PMID: 36580416] <https://pubmed.ncbi.nlm.nih.gov/36580416>
- Frey SE, Goll JB, Beigel JH. Erythema and induration after mpox (JYNNEOS) vaccination revisited. *N Engl J Med* 2023;388(15):1432-35. [PMID: 36947462] <https://pubmed.ncbi.nlm.nih.gov/36947462>
- Frey SE, Wald A, Edupuganti S, et al. Comparison of lyophilized versus liquid modified vaccinia Ankara (MVA) formulations and subcutaneous versus intradermal routes of administration in healthy vaccinia-naive subjects. *Vaccine* 2015;33(39):5225-34. [PMID: 26143613] <https://pubmed.ncbi.nlm.nih.gov/26143613>
- Gandhi PA, Patro SK, Sandeep M, et al. Oral manifestation of the monkeypox virus: a systematic review and meta-analysis. *EClinicalMedicine* 2023;56:101817. [PMID: 36628187] <https://pubmed.ncbi.nlm.nih.gov/36628187>
- Garrigues(a) JM, Hemarajata P, Espinosa A, et al. Community spread of a human monkeypox virus variant with a tecovirimat resistance-associated mutation. *Antimicrob Agents Chemother* 2023;67(11):e0097223. [PMID: 37823631]
<https://pubmed.ncbi.nlm.nih.gov/37823631>
- Garrigues(b) JM, Hemarajata P, Karan A, et al. Identification of tecovirimat resistance-associated mutations in human monkeypox virus - Los Angeles County. *Antimicrob Agents Chemother* 2023;67(7):e0056823. [PMID: 37338408]
<https://pubmed.ncbi.nlm.nih.gov/37338408>
- Greenberg RN, Overton ET, Haas DW, et al. Safety, immunogenicity, and surrogate markers of clinical efficacy for modified vaccinia Ankara as a smallpox vaccine in HIV-infected subjects. *J Infect Dis* 2013;207(5):749-58. [PMID: 23225902]
<https://pubmed.ncbi.nlm.nih.gov/23225902>
- Hazra A, Zucker J, Bell E, et al. Mpox in people with past infection or a complete vaccination course: a global case series. *Lancet Infect Dis* 2024;24(1):57-64. [PMID: 37678309] <https://pubmed.ncbi.nlm.nih.gov/37678309>
- Hyndiuk RA, Seideman S, Leibsohn JM. Treatment of vaccinia keratitis with trifluorothymidine. *Arch Ophthalmol* 1976;94(10):1785-86. [PMID: 823931] <https://pubmed.ncbi.nlm.nih.gov/823931>
- Karmarkar EN, Golden MR, Kerani RP, et al. Association of tecovirimat therapy with mpox symptom improvement: a cross-sectional study-King County, Washington, May-October 2022. *Open Forum Infect Dis* 2024;11(3):ofae029. [PMID: 38456195] <https://pubmed.ncbi.nlm.nih.gov/38456195>
- Ladhani SN, Dowell AC, Jones S, et al. Early evaluation of the safety, reactogenicity, and immune response after a single dose of modified vaccinia Ankara-Bavaria Nordic vaccine against mpox in children: a national outbreak response. *Lancet Infect Dis* 2023;23(9):1042-50. [PMID: 37336224] <https://pubmed.ncbi.nlm.nih.gov/37336224>
- Laurenson-Schafer H, Sklenovska N, Hoxha A, et al. Description of the first global outbreak of mpox: an analysis of global surveillance data. *Lancet Glob Health* 2023;11(7):e1012-23. [PMID: 37349031]
<https://pubmed.ncbi.nlm.nih.gov/37349031>
- Luong Nguyen LB, Ghosn J, Durier C, et al. A prospective national cohort evaluating ring MVA vaccination as post-exposure prophylaxis for monkeypox. *Nat Med* 2022;28(10):1983-84. [PMID: 35831633]
<https://pubmed.ncbi.nlm.nih.gov/35831633>
- Madewell ZJ, Charniga K, Masters NB, et al. Serial interval and incubation period estimates of monkeypox virus infection in 12 jurisdictions, United States, May-August 2022. *Emerg Infect Dis* 2023;29(4):818-21. [PMID: 36863012]
<https://pubmed.ncbi.nlm.nih.gov/36863012>
- Mailhe M, Beaumont AL, Thy M, et al. Clinical characteristics of ambulatory and hospitalized patients with monkeypox virus infection: an observational cohort study. *Clin Microbiol Infect* 2023;29(2):233-39. [PMID: 36028090]
<https://pubmed.ncbi.nlm.nih.gov/36028090>

- Mazzotta V, Cozzi-Lepri A, Lanini S, et al. Effect of tecovirimat on healing time and viral clearance by emulation of a target trial in patients hospitalized for mpox. *J Med Virol* 2023;95(6):e28868. [PMID: 37306318]
<https://pubmed.ncbi.nlm.nih.gov/37306318>
- McLean J, Stoeckle K, Huang S, et al. Tecovirimat treatment of people with HIV during the 2022 mpox outbreak: a retrospective cohort study. *Ann Intern Med* 2023;176(5):642-48. [PMID: 37126820]
<https://pubmed.ncbi.nlm.nih.gov/37126820>
- McQuiston JH, Braden CR, Bowen MD, et al. The CDC domestic mpox response - United States, 2022-2023. *MMWR Morb Mortal Wkly Rep* 2023;72(20):547-52. [PMID: 37200231] <https://pubmed.ncbi.nlm.nih.gov/37200231>
- Mendoza R, Petras JK, Jenkins P, et al. Monkeypox virus infection resulting from an occupational needlestick - Florida, 2022. *MMWR Morb Mortal Wkly Rep* 2022;71(42):1348-49. [PMID: 36264845] <https://pubmed.ncbi.nlm.nih.gov/36264845>
- Miura F, Backer JA, van Rijckevorsel G, et al. Time scales of human mpox transmission in the Netherlands. *J Infect Dis* 2023;229(3):800-804. [PMID: 37014716] <https://pubmed.ncbi.nlm.nih.gov/37014716>
- Mizushima D, Shintani Y, Takano M, et al. Prevalence of asymptomatic mpox among men who have sex with men, Japan, January-March 2023. *Emerg Infect Dis* 2023;29(9):1872-76. [PMID: 37506678]
<https://pubmed.ncbi.nlm.nih.gov/37506678>
- Montero Morales L, Barbas Del Buey JF, Alonso Garcia M, et al. Post-exposure vaccine effectiveness and contact management in the mpox outbreak, Madrid, Spain, May to August 2022. *Euro Surveill* 2023;28(24):2200883. [PMID: 37318762]
<https://pubmed.ncbi.nlm.nih.gov/37318762>
- Moschese D, Rizzo A, Raccagni AR, et al. Plausibility of sexual behavior changes and role of vaccination in mpox outbreak control among MSM. Abstract 426. CROI; 2024 Mar 3-6; Denver, CO.
<https://www.croiconference.org/abstract/plausibility-of-sexual-behavior-changes-and-role-of-vaccination-in-mpox-outbreak-control-among-msm/>
- O'Laughlin K, Tobolowsky FA, Elmor R, et al. Clinical use of tecovirimat (Tpoxx) for treatment of monkeypox under an investigational new drug protocol - United States, May-August 2022. *MMWR Morb Mortal Wkly Rep* 2022;71(37):1190-95. [PMID: 36107794] <https://pubmed.ncbi.nlm.nih.gov/36107794>
- Ogoina D, Iroezindu M, James HI, et al. Clinical course and outcome of human monkeypox in Nigeria. *Clin Infect Dis* 2020;71(8):e210-14. [PMID: 32052029] <https://pubmed.ncbi.nlm.nih.gov/32052029>
- Overton ET, Lawrence SJ, Stapleton JT, et al. A randomized phase II trial to compare safety and immunogenicity of the MVA-BN smallpox vaccine at various doses in adults with a history of AIDS. *Vaccine* 2020;38(11):2600-2607. [PMID: 32057574]
<https://pubmed.ncbi.nlm.nih.gov/32057574>
- Palich R, Burrell S, Monsel G, et al. Viral loads in clinical samples of men with monkeypox virus infection: a French case series. *Lancet Infect Dis* 2023;23(1):74-80. [PMID: 36183707] <https://pubmed.ncbi.nlm.nih.gov/36183707>
- Paredes MI, Ahmed N, Figgins M, et al. Underdetected dispersal and extensive local transmission drove the 2022 mpox epidemic. *Cell* 2024;187(6):1374-1386.e13. [PMID: 38428425] <https://pubmed.ncbi.nlm.nih.gov/38428425>
- Pepose JS, Margolis TP, LaRussa P, et al. Ocular complications of smallpox vaccination. *Am J Ophthalmol* 2003;136(2):343-52. [PMID: 12888060] <https://pubmed.ncbi.nlm.nih.gov/12888060>
- Perzia B, Theotoka D, Li K, et al. Treatment of ocular-involving monkeypox virus with topical trifluridine and oral tecovirimat in the 2022 monkeypox virus outbreak. *Am J Ophthalmol Case Rep* 2023;29:101779. [PMID: 36573234]
<https://pubmed.ncbi.nlm.nih.gov/36573234>
- Philpott D, Hughes CM, Alroy KA, et al. Epidemiologic and clinical characteristics of monkeypox cases - United States, May 17-July 22, 2022. *MMWR Morb Mortal Wkly Rep* 2022;71(32):1018-22. [PMID: 35951487]
<https://pubmed.ncbi.nlm.nih.gov/35951487>
- Pollock ED, Clay PA, Keen A, et al. Potential for recurrent mpox outbreaks among gay, bisexual, and other men - United States, 2023. *MMWR Morb Mortal Wkly Rep* 2023;72(21):568-73. [PMID: 37227964]
<https://pubmed.ncbi.nlm.nih.gov/37227964>
- Quenelle DC, Prichard MN, Keith KA, et al. Synergistic efficacy of the combination of ST-246 with CMX001 against orthopoxviruses. *Antimicrob Agents Chemother* 2007;51(11):4118-24. [PMID: 17724153]
<https://pubmed.ncbi.nlm.nih.gov/17724153>
- Rao AK, Petersen BW, Whitehill F, et al. Use of JYNNEOS (smallpox and monkeypox vaccine, live, nonreplicating) for preexposure vaccination of persons at risk for occupational exposure to orthopoxviruses: recommendations of the Advisory Committee on Immunization Practices - United States, 2022. *MMWR Morb Mortal Wkly Rep* 2022;71(22):734-42. [PMID: 35653347] <https://pubmed.ncbi.nlm.nih.gov/35653347>

- Rao AK, Schrodt CA, Minhaj FS, et al. Interim clinical treatment considerations for severe manifestations of mpox - United States, February 2023. *MMWR Morb Mortal Wkly Rep* 2023;72(9):232-43. [PMID: 36862595] <https://pubmed.ncbi.nlm.nih.gov/36862595>
- Riser AP, Hanley A, Cima M, et al. Epidemiologic and clinical features of mpox-associated deaths - United States, May 10, 2022-March 7, 2023. *MMWR Morb Mortal Wkly Rep* 2023;72(15):404-10. [PMID: 37053126] <https://pubmed.ncbi.nlm.nih.gov/37053126>
- Rosen JB, Arciuolo RJ, Pathela P, et al. JYNNEOS effectiveness as post-exposure prophylaxis against mpox: challenges using real-world outbreak data. *Vaccine* 2024;42(3):548-55. [PMID: 38218669] <https://pubmed.ncbi.nlm.nih.gov/38218669>
- Rosenberg ES, Dorabawila V, Hart-Malloy R, et al. Effectiveness of JYNNEOS vaccine against diagnosed mpox infection - New York, 2022. *MMWR Morb Mortal Wkly Rep* 2023;72(20):559-63. [PMID: 37339074] <https://pubmed.ncbi.nlm.nih.gov/37339074>
- Shah J, Saak TM, Desai AN, et al. Otolaryngologic manifestations among mpox patients: a systematic review and meta-analysis. *Am J Otolaryngol* 2023;44(6):103991. [PMID: 37487464] <https://pubmed.ncbi.nlm.nih.gov/37487464>
- Suner C, Ubals M, Tarin-Vicente EJ, et al. Viral dynamics in patients with monkeypox infection: a prospective cohort study in Spain. *Lancet Infect Dis* 2023;23(4):445-53. [PMID: 36521505] <https://pubmed.ncbi.nlm.nih.gov/36521505>
- Tarin-Vicente EJ, Alemany A, Agud-Dios M, et al. Clinical presentation and virological assessment of confirmed human monkeypox virus cases in Spain: a prospective observational cohort study. *Lancet* 2022;400(10353):661-69. [PMID: 35952705] <https://pubmed.ncbi.nlm.nih.gov/35952705>
- Thet AK, Kelly PJ, Kasule SN, et al. The use of vaccinia immune globulin in the treatment of severe mpox. virus infection in human immunodeficiency virus/AIDS. *Clin Infect Dis* 2023;76(9):1671-73. [PMID: 36571287] <https://pubmed.ncbi.nlm.nih.gov/36571287>
- Thornhill JP, Barkati S, Walmsley S, et al. Monkeypox virus infection in humans across 16 countries - April-June 2022. *N Engl J Med* 2022;387(8):679-91. [PMID: 35866746] <https://pubmed.ncbi.nlm.nih.gov/35866746>
- Titanji BK, Tegomoh B, Nematollahi S, et al. Monkeypox: a contemporary review for healthcare professionals. *Open Forum Infect Dis* 2022;9(7):ofac310. [PMID: 35891689] <https://pubmed.ncbi.nlm.nih.gov/35891689>
- Vaughan AM, Cenciarelli O, Colombe S, et al. A large multi-country outbreak of monkeypox across 41 countries in the WHO European region, 7 March to 23 August 2022. *Euro Surveill* 2022;27(36):2200620. [PMID: 36082686] <https://pubmed.ncbi.nlm.nih.gov/36082686>
- Wolff Sagy Y, Zucker R, Hammerman A, et al. Real-world effectiveness of a single dose of mpox vaccine in males. *Nat Med* 2023;29(3):748-52. [PMID: 36720271] <https://pubmed.ncbi.nlm.nih.gov/36720271>
- Zachary KC, Shenoy ES. Monkeypox transmission following exposure in healthcare facilities in nonendemic settings: low risk but limited literature. *Infect Control Hosp Epidemiol* 2022;43(7):920-24. [PMID: 35676244] <https://pubmed.ncbi.nlm.nih.gov/35676244>
- Zhang XS, Mandal S, Mohammed H, et al. Transmission dynamics and effect of control measures on the 2022 outbreak of mpox among gay, bisexual, and other men who have sex with men in England: a mathematical modelling study. *Lancet Infect Dis* 2024;24(1):65-74. [PMID: 37708908] <https://pubmed.ncbi.nlm.nih.gov/37708908>

Supplement: Guideline Development and Recommendation Ratings

Table S1: Guideline Development: New York State Department of Health AIDS Institute Clinical Guidelines Program

Developer	New York State Department of Health AIDS Institute (NYSDOH AI) Clinical Guidelines Program
Funding source	NYSDOH AI
Program manager	Clinical Guidelines Program, Johns Hopkins University School of Medicine, Division of Infectious Diseases. See Program Leadership and Staff .
Mission	To produce and disseminate evidence-based, state-of-the-art clinical practice guidelines that establish uniform standards of care for practitioners who provide prevention or treatment of HIV, viral hepatitis, other sexually transmitted infections, and substance use disorders for adults throughout New York State in the wide array of settings in which those services are delivered.
Expert committees	The NYSDOH AI Medical Director invites and appoints committees of clinical and public health experts from throughout New York State to ensure that the guidelines are practical, immediately applicable, and meet the needs of care providers and stakeholders in all major regions of New York State, all relevant clinical practice settings, key New York State agencies, and community service organizations.
Committee structure	<ul style="list-style-type: none"> • Leadership: AI-appointed chair, vice chair(s), chair emeritus, clinical specialist(s), JHU Guidelines Program Director, AI Medical Director, AI Clinical Consultant, AVAC community advisor • Contributing members • Guideline writing groups: Lead author, coauthors if applicable, and all committee leaders
Disclosure and management of conflicts of interest	<ul style="list-style-type: none"> • Annual disclosure of financial relationships with commercial entities for the 12 months prior and upcoming is required of all individuals who work with the guidelines program, and includes disclosure for partners or spouses and primary professional affiliation. • The NYSDOH AI assesses all reported financial relationships to determine the potential for undue influence on guideline recommendations and, when indicated, denies participation in the program or formulates a plan to manage potential conflicts. Disclosures are listed for each committee member.
Evidence collection and review	<ul style="list-style-type: none"> • Literature search and review strategy is defined by the guideline lead author based on the defined scope of a new guideline or update. • A comprehensive literature search and review is conducted for a new guideline or an extensive update using PubMed, other pertinent databases of peer-reviewed literature, and relevant conference abstracts to establish the evidence base for guideline recommendations. • A targeted search and review to identify recently published evidence is conducted for guidelines published within the previous 3 years. • Title, abstract, and article reviews are performed by the lead author. The JHU editorial team collates evidence and creates and maintains an evidence table for each guideline.
Recommendation development	<ul style="list-style-type: none"> • The lead author drafts recommendations to address the defined scope of the guideline based on available published data. • Writing group members review the draft recommendations and evidence and deliberate to revise, refine, and reach consensus on all recommendations. • When published data are not available, support for a recommendation may be based on the committee’s expert opinion. • The writing group assigns a 2-part rating to each recommendation to indicate the strength of the recommendation and quality of the supporting evidence. The group reviews the evidence, deliberates, and may revise recommendations when required to reach consensus.

Table S1: Guideline Development: New York State Department of Health AIDS Institute Clinical Guidelines Program

Review and approval process	<ul style="list-style-type: none"> Following writing group approval, draft guidelines are reviewed by all contributors, program liaisons, and a volunteer reviewer from the AI Community Advisory Committee. Recommendations must be approved by two-thirds of the full committee. If necessary to achieve consensus, the full committee is invited to deliberate, review the evidence, and revise recommendations. Final approval by the committee chair and the NYSDOH AI Medical Director is required for publication.
External reviews	<ul style="list-style-type: none"> External review of each guideline is invited at the developer’s discretion. External reviewers recognized for their experience and expertise review guidelines for accuracy, balance, clarity, and practicality and provide feedback.
Update process	<ul style="list-style-type: none"> JHU editorial staff ensure that each guideline is reviewed and determined to be current upon the 3-year anniversary of publication; guidelines that provide clinical recommendations in rapidly changing areas of practice may be reviewed annually. Published literature is surveilled to identify new evidence that may prompt changes to existing recommendations or development of new recommendations. If changes in the standard of care, newly published studies, new drug approval, new drug-related warning, or a public health emergency indicate the need for immediate change to published guidelines, committee leadership will make recommendations and immediate updates and will invite full committee review as indicated.

Table S2: Recommendation Ratings and Definitions

Strength	Quality of Evidence	
A: Strong B: Moderate C: Optional	1	Based on published results of at least 1 randomized clinical trial with clinical outcomes or validated laboratory endpoints.
	*	Based on either a self-evident conclusion; conclusive, published, in vitro data; or well-established practice that cannot be tested because ethics would preclude a clinical trial.
	2	Based on published results of at least 1 well-designed, nonrandomized clinical trial or observational cohort study with long-term clinical outcomes.
	2†	Extrapolated from published results of well-designed studies (including nonrandomized clinical trials) conducted in populations other than those specifically addressed by a recommendation. The source(s) of the extrapolated evidence and the rationale for the extrapolation are provided in the guideline text. One example would be results of studies conducted predominantly in a subpopulation (e.g., one gender) that the committee determines to be generalizable to the population under consideration in the guideline.
	3	Based on committee expert opinion, with rationale provided in the guideline text.